

Importance of Cytology in Diagnosis of Sialadenosis-A Rare Entity

PARUL GARG¹, HARJOT KAUR², SHILPA BAIRAGI³, ISHWER TAYAL⁴

CC BY-NC-ND

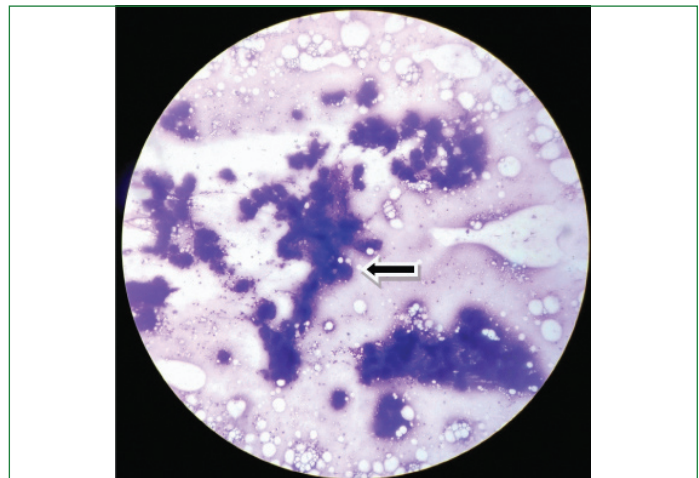
ABSTRACT

Sialadenosis also known as sialosis is a non-inflammatory and non-cancerous enlargement of salivary glands particularly the parotid gland. It is commonly seen in age group of 40 to 70 years. It is an extremely uncommon cause for enlargement of the parotid gland. Sialadenosis is a systemic disease that is associated with a variety of systemic disorders which includes the endocrine system as in diabetes mellitus, pregnancy, hypothyroidism, acromegaly; dystrophic–metabolic disorders like malnutrition, avitaminosis, alcoholism, chronic liver diseases; neurogenic disorders like dysfunction of the vegetative nervous system and various drugs like antihypertensive agents, valproic acid, isoprenaline, anti-thyroids. Out of these, diabetes and alcoholism are most common causes, management of sialosis is done by correcting the underlying cause. The present case is of a 50-year-old female patient having bilateral enlargement of parotids. The swellings were diffuse, soft, non-tender and gradually increasing in size from past three months. Past medical history revealed that patient was diabetic and was on irregular medication. Ultrasonography showed diffusely enlarged, hyperechoic salivary glands suggestive of benign salivary gland lesion; possibility of sialadenitis and sialadenosis was given and patient was advised Fine Needle Aspiration Cytology (FNAC). FNAC showed features of benign salivary gland lesion suggestive of sialadenosis. The sialomegaly was associated with diabetes mellitus and it disappeared after start of regular treatment. So, careful observation of cytological features along with clinical history can help in reaching a correct diagnosis and prevent unnecessary surgical intervention.

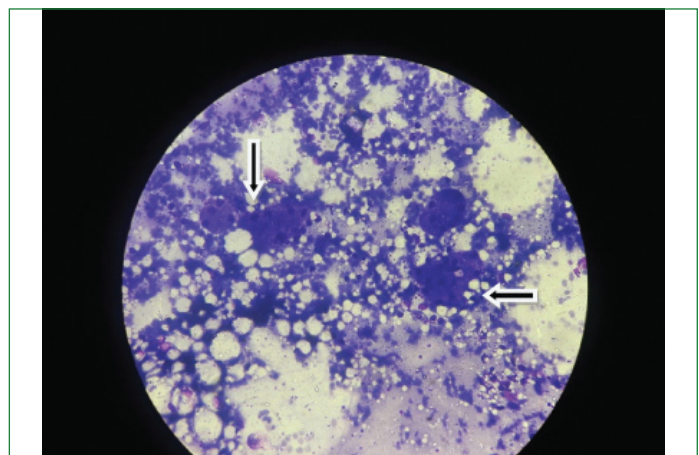
Keywords: Differential diagnosis, Enlargement, Fine needle aspiration cytology, Parotid gland

CASE REPORT

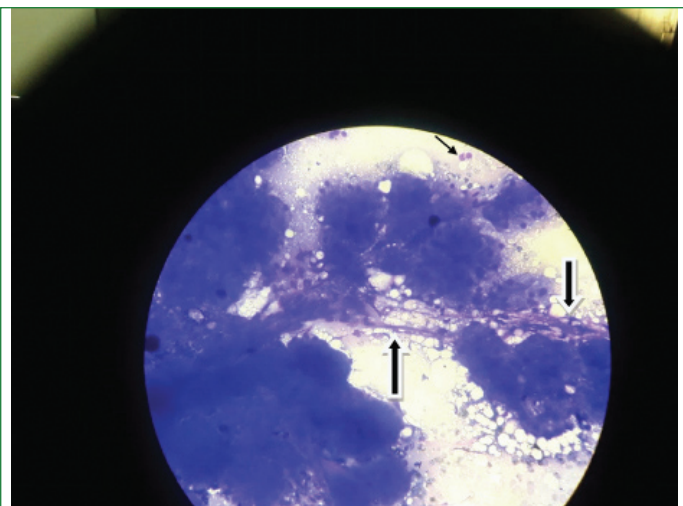
A 50-year-old diabetic female came to the cytology section for FNAC of bilateral swellings on the preauricular region. The swellings were bilateral, ill-defined measuring, 1.5 × 1 cm in size, soft in consistency, non-tender and freely mobile. They were gradually increasing in size over a period of three months. The skin over the swelling was normal with normal temperature. The patient had no discomfort during eating and drinking. Medical history of the patient was taken. The patient was a known case of type 2 diabetes on irregular medication. No other relevant history was present. Ultrasonography showed diffusely enlarged, hyperechoic salivary glands suggestive of benign salivary gland lesion; possibility of sialadenitis and sialadenosis was given and patient was advised FNAC and was subjected to it. It was performed by using 20 ml plastic disposable syringe and disposable 23-gauge needles. Blood tinged aspirate was obtained. Five slides were made from aspirated material, two were fixed with 85% isopropyl alcohol and stained with Haematoxylin and Eosin (H&E), while three slides were air-dried and stained with May Grunwald Giemsa (MGG) stain. On microscopic examination, the aspiration smears were moderately cellular having acinar epithelial cells arranged in collections, papillae and singly scattered [Table/Fig-1a,b]. Cells adherent to vascular stroma were also noted [Table/Fig-2]. Individual cells were round, have small round nuclei and a moderate amount of foamy cytoplasm [Table/Fig-3]. The background showed numerous naked nuclei of epithelial cell origin and red blood cells. Inflammatory cells were absent in the smears examined. Thus, on cytology diagnosis of benign salivary gland lesion suggestive of sialadenosis was made. The patient was then subjected to a set of blood tests like complete blood counts, fasting blood sugar levels, renal function tests and liver function tests. All were in normal range except for fasting blood sugar which was 225 mg/dL. The patient was prescribed oral hypoglycaemics and counselled to take regular medication. On follow-up of the patient after 15 days, the swellings subsided



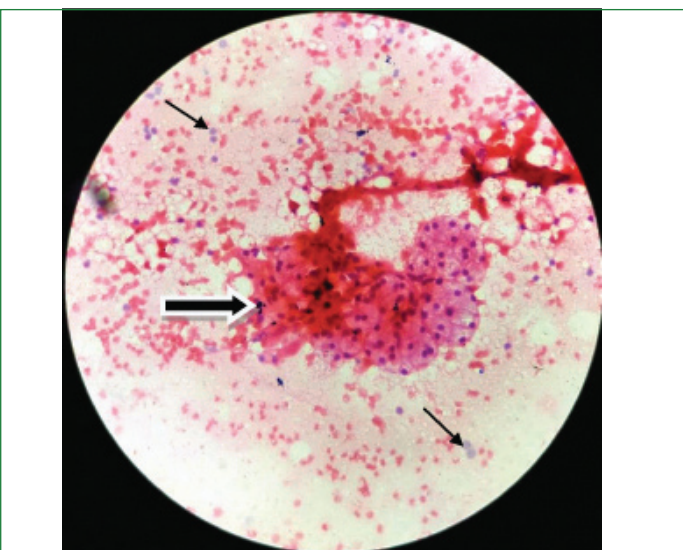
[Table/Fig-1a]: Photomicrograph showing cellular smears having acinar cells arranged in papillae, clusters (arrow) and singly scattered (MGG, X100).



[Table/Fig-1b]: Photomicrograph showing acinar cells arranged in clusters (arrow) (MGG, X400).



[Table/Fig-2]: Photomicrograph shows acinar cells adherent to vascular stroma (thick arrow). Naked nuclei of epithelial cell origin are also noted in the background (thin arrow) (MGG, X400).



[Table/Fig-3]: Photomicrograph showing cluster of acinar epithelial cells having small round nuclei and abundant amount of foamy cytoplasm (thick arrow). Naked nuclei of epithelial cell origin are also noted in the background (thin arrow) (H&E, 400X).

hereby proving that sialomegaly was due to underlying systemic cause which is called sialadenosis.

DISCUSSION

Sialadenosis also called as sialosis is a non-neoplastic and non-inflammatory lesion of the salivary glands [1]. It is characterised by progressive, painless and slow growing bilateral enlargement of major salivary gland. However, unilaterality has also been reported [2]. Sialadenosis usually involves parotid gland, occasionally submandibular glands and very rarely minor salivary glands [2]. The patients are mostly asymptomatic. It is associated with a variety of systemic disorders, which includes the endocrine system as in diabetes mellitus, dysfunction of gonads, pituitary gland, thyroid gland, pregnancy; dystrophic–metabolic disorders like malnutrition, avitaminosis, alcoholism, chronic liver diseases; neurogenic disorders like dysfunction of the vegetative nervous system and drugs like antihypertensive agents, valproic acid, anti-thyroids [3]. Diabetes mellitus and alcoholism are the most common causes [4]. Pathogenesis of sialosis is explained as the neuropathic alteration of autonomic nervous system of salivary gland acini [2].

The management of sialadenosis is by correcting the underlying cause. No surgical procedure is required so an early diagnosis is helpful in preventing any surgical intervention. FNAC being a minimally invasive cost-effective procedure can be used for

diagnosis of such lesions. Clinical examination, with proper history of patient and cytomorphology can be diagnostic. Very little has been published about role of cytology in diagnosis of sialadenosis [5-7]. In this case report, a case of sialadenosis diagnosed on cytomorphology was reported.

Most of the patients of sialadenosis present between 40 and 70 years of age [8]. In this case, age of patient was 50 years. It usually occurs bilaterally in parotid gland [9] as is seen in index case. Sialadenosis occurs in association with systemic disorders; patient in this case was suffering from diabetes and was on irregular medication. After the cytological diagnosis, the patient was started with oral hypoglycaemics. On follow-up of the patient, the swellings subsided and blood sugar levels were within normal limits. Clinically, the patient presents with soft, often bilateral, non-tender, painless and recurrent swelling of the parotid gland [1,9]. Similar findings were seen in index case also.

Cytomorphology was diagnostic in present case. FNAC yielded cellular smears having acinar epithelial cells which appeared normal or slightly increased in size. Cells adherent to thin fibrovascular stroma were also seen. Background had many naked nuclei of epithelial origin. No atypical cells or inflammatory cells were seen. Absence of inflammatory cells rules out the inflammatory causes of parotid enlargement. Absence of atypical cells rules out any neoplastic condition. Similar cytological findings of sialadenosis were described by Jagtap SV et al., and Pape SA et al., [5,6]. Most important cytological differential diagnosis for sialadenosis is low grade acinic cell tumour [5]. Acinic cell tumours generally yield abundant cellular material with a clean background [9]. Cluster of cells are larger and irregular. Cells are less uniform and atypia is prominent. Discrete round acini defined by basement membrane and normal tissues including adipose and ductal cells as seen in sialadenosis are not seen in acinic cell carcinoma [10-12]. Moreover, history of underlying systemic disease rules out possibility of acinic cell tumours. In present case there was no atypia, cells were uniform, regular and acini were well-defined by basement membrane. Another diagnostic challenge in cytomorphology is aspiration of normal salivary gland tissue i.e., ductal cells and acinar cells can lead on to false negative diagnosis and diagnosis of sialosis can be missed. So, a careful cytological interpretation along with clinical work up can help reach a diagnosis [13].

Other differential diagnoses of bilateral parotid enlargements includes sjogren's syndrome, Human Immunodeficiency Virus (HIV) infection and lymphoepithelial disease and sarcoidosis. Sjogren's syndrome is an autoimmune disorder associated with connective tissue disease. It can be ruled out by clinical history of xerostomia and xerophthalmia and with autoantibodies levels [14]. In HIV infection and lymphoepithelial diseases, the presence of lymphoepithelial cysts can be identified by CT scan. HIV testing can be done to rule out HIV infection [14]. Sarcoidosis can be ruled out by radiology and cytology features. Presence of lung infiltrates and hilar lymphadenopathy can be detected radiographically. On cytology, granulomatous pathology will be appreciated [14].

CONCLUSION(S)

Sialadenosis presents as soft, diffuse, painless, non-tender swelling of salivary glands mainly parotids. It is usually bilateral but unilateral cases have also been reported. Diagnosis of sialadenosis and excluding other differential diagnoses like inflammatory, autoimmune and neoplastic causes can be reached by clinical workup along with detailed medical history and cytomorphology of the lesion. FNAC being a cheap and minimally invasive procedure can be a useful tool for reaching the diagnosis of sialosis. Meticulous interpretation of cytological features can be useful for early diagnosis which will be helpful in preventing unnecessary surgical burden on patient as well as on doctor.

REFERENCES

- [1] Gupta S, Sodhani P. Sialadenosis of parotid gland: A cytomorphologic and morphometric study of four cases. *Anal Quant Cytol Histol.* 1998;20:225-28.
- [2] Guan G, Won J, Mei L, Polonowita A. Extensive adipose replacement of the parotid glands: An unusual presentation of sialadenosis. A case report and literature review. *Oral Surg.* 2020;13:41-47.
- [3] Garcia Garcia B, Dean Ferrer A, Diaz Jimenez N, Alamillos Granados FJ. Bilateral parotid sialadenosis associated with long-standing bulimia: a case report and literature review. *J Maxillofac Oral Surg.* 2018;17(2):117-21.
- [4] Scully C, Bagán JV, Eveson JW, Barnard N, Turner FM. Sialosis: 35 cases of persistent parotid swelling from two countries. *Br J Oral Maxillofac Surg.* 2008;46(6):468-72.
- [5] Jagtap SV, Aramani SS, Mane A, Bonde V. Sialosis: Cytomorphological significance in the diagnosis of an uncommon entity. *J Cytol.* 2017;34:51-52.
- [6] Pape SA, MacLeod RI, McLean NR, Soames JV. Sialadenosis of the salivary glands. *Br J Plast Surg.* 1995;48:419-22.
- [7] Mandel L, Patel S. Sialadenosis associated with diabetes mellitus: A case report. *J Oral Maxillofac Surg.* 2002;60(6):696-98.
- [8] Smith WP. Disorders of salivary glands. In: Williams NS, Bulstrode CJ, O'Connell PR, editors. *Bailey and Love's Short Practice of Surgery.* 26th ed. New York: CRC Press; 2013. Pp. 723-40.
- [9] Henry-Stanley MJ, Beneke J, Bardales RH, Stanley MW. Fine-needle aspiration of normal tissue from enlarged salivary glands: Sialosis or missed target? *Diagn Cytopathol.* 1995;13:300-03.
- [10] Chhieng DC, Cohen J-M, Cangiarella JF. Fine needle aspiration of spindle cell and mesenchymal lesions of the salivary glands. *Diagn Cytopathol.* 2000;23:253-59.
- [11] Klijanienko J, Vielh P. Fine needle sampling of salivary gland lesions V. Cytology of 22 cases of acinic cell carcinoma of salivary glands. *Diagn Cytopathol.* 1997;16:402-12.
- [12] Jaiswal P, Sharma M, Ahmad F, Sanaullah Khan N, Siddhartha Shanker S, Agarwal M. Risk-based stratification of salivary gland lesions on cytology: An institutional experience. *Iran J Pathol.* 2018;13(2):220-28.
- [13] Inanlı HM, Kanmaz MA, Ural A, Dilek GB. Fine needle aspiration biopsy in the diagnosis of salivary gland neoplasms compared with histopathology. *Indian J Otolaryngol Head Neck.* 2013;65(Suppl 1):121-25.
- [14] Mandel L, Hamele-Bena D. Alcoholic parotid sialadenosis. *J Am Dent Assoc.* 1997;128:1411-15.

PARTICULARS OF CONTRIBUTORS:

1. Assistant Professor, Department of Pathology, GGS Medical College, Faridkot, Punjab, India.
2. Professor, Department of Pathology, SGRD Institute of Medical Sciences and Research, Amritsar, Punjab, India.
3. Junior Resident, Department of Pathology, GGS Medical College, Faridkot, Punjab, India.
4. Assistant Professor, Department of Forensic Medicine, GGS Medical College, Faridkot, Punjab, India.

NAME, ADDRESS, E-MAIL ID OF THE CORRESPONDING AUTHOR:

Dr. Parul Garg,
Infront of HDFC Bank, Raman Cinema Road, Mansa-151505, Punjab, India.
E-mail: parultayal45@gmail.com

PLAGIARISM CHECKING METHODS: ^[Jain H et al.]

- Plagiarism X-checker: Aug 01, 2020
- Manual Googling: Oct 10, 2020
- iThenticate Software: Dec 16, 2020 (10%)

ETYMOLOGY: Author Origin

AUTHOR DECLARATION:

- Financial or Other Competing Interests: None
- Was informed consent obtained from the subjects involved in the study? Yes
- For any images presented appropriate consent has been obtained from the subjects. NA

Date of Submission: **Jul 26, 2020**

Date of Peer Review: **Aug 27, 2020**

Date of Acceptance: **Oct 14, 2020**

Date of Publishing: **Jan 01, 2021**